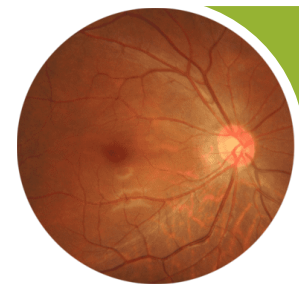


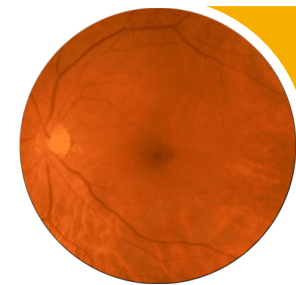
International Classification

Diabetic retinopathy



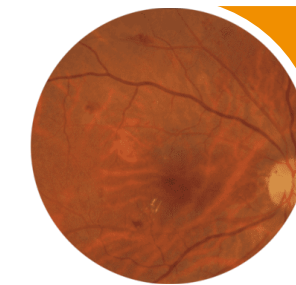
No apparent retinopathy

No abnormalities



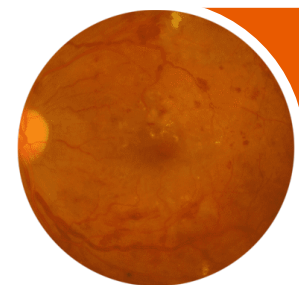
Mild NPDR

Microaneurysms only



Moderate NPDR

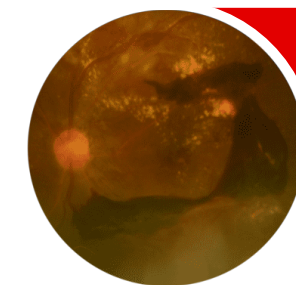
Microaneurysms and other signs (such as dot and blot hemorrhages, hard exudates, cotton wool spots), but less than severe NPDR



Severe NPDR

Moderate NPDR with any of the following:

- Intraretinal hemorrhages (≥ 20 in each quadrant);
- Definite venous beading (in 2 quadrants);
- IRMA (in 1 quadrant);
- and no signs of PDR

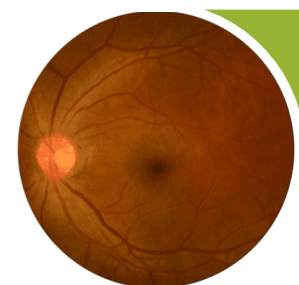


PDR

Severe NPDR and 1 or more of the following:

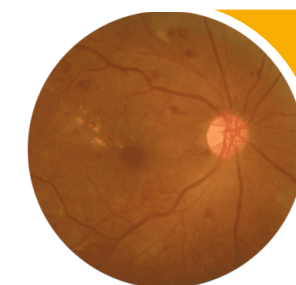
- Neovascularization
- Vitreous/preretinal hemorrhage

Diabetic macular edema



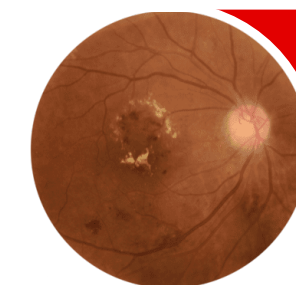
DME absent

No retinal thickening or hard exudates in the macula



Noncentral-involved, diabetic macular edema

Retinal thickening in the macula that does not involve the central subfield zone that is 1 mm in diameter



Central-involved diabetic macular edema

Retinal thickening in the macula that does involve the central subfield zone that is 1 mm in diameter